

# Unruptured Ovarian Ectopic Pregnancy In Adolescence Case Report

Xuechuan Han, Yan Yu and Yang Fan\*

Department of Gynecology and Obstetrics, Ningxia People's Hospital, Yinchuan, China

**\*Corresponding author:**

Yang Fan,

Department of Gynecology and Obstetrics, Ningxia People's Hospital, Yinchuan, China,

Tel: 0951-2021491;

**Received Date:** 25 Oct 2023

**Accepted Date:** 03 Nov 2023

**Published Date:** 09 Nov 2023

**Citation:**

Yang Fan. Unruptured Ovarian Ectopic Pregnancy In Adolescence Case Report. Annals of Clinical and Medical Case Reports 2023.

## 1. Abstract

Ovarian pregnancy is one of the rarest types of ectopic pregnancy. Its preoperative diagnosis remains a challenge because of it presents quite similarly to tubal pregnancy and complicated ovarian cysts. In most cases, histology is necessary to confirm the diagnosis, we present an unruptured ovarian pregnancy in a teenager diagnosed during laparoscopy operation.

## 2. Keywords:

Laparoscopy, Varian Pregnancy, Adolescence

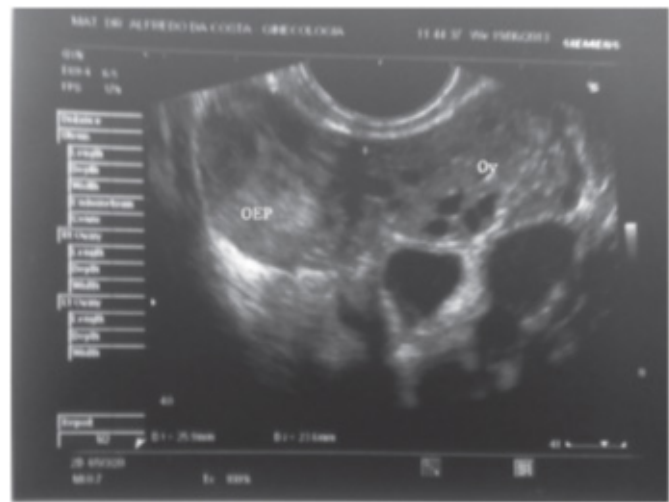
## 3. Introduction

Primary ovarian pregnancy is one of the rarest forms of non-tubal ectopic pregnancy. It refers to the implantation of the fertilized ovum in the ovary. The first case of ovarian pregnancy was reported by Saint Maurice in 1682 [1]. Its incidence has been on the rise because of increased awareness of this disease and availability of assays for serum beta-human chorionic gonadotropin ( $\beta$ -hCG) as well as the development of transvaginal ultrasound in clinical practice. The rate accounts for about 0.5 ~ 3% of all ectopic pregnancies. And its incidence following natural conception ranges from 1/2000 to 1/60000 pregnancies [2]. Given that the surface cortex of the ovarian pregnancy tissue is thin. The ovary lacks elasticity. So that ovarian pregnancies were usually found to be ruptured in clinical practice. It is difficult to distinguish from ovarian corpus luteum rupture combined with tubal pregnancy abortion. So the definite diagnosis for ruptured ovarian pregnancy is difficult to obtain preoperative. Here we present one case of unruptured ovarian pregnancy during laparoscopy in

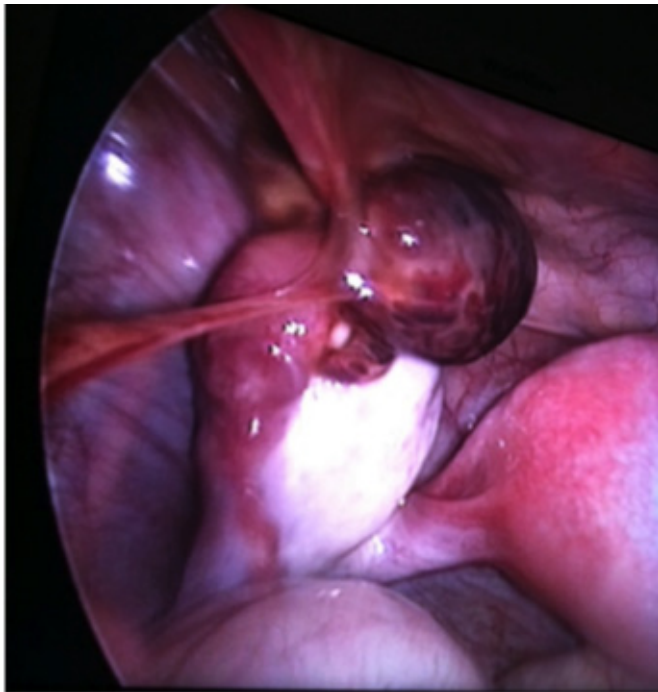adolescent.

## 4. Case Presentation

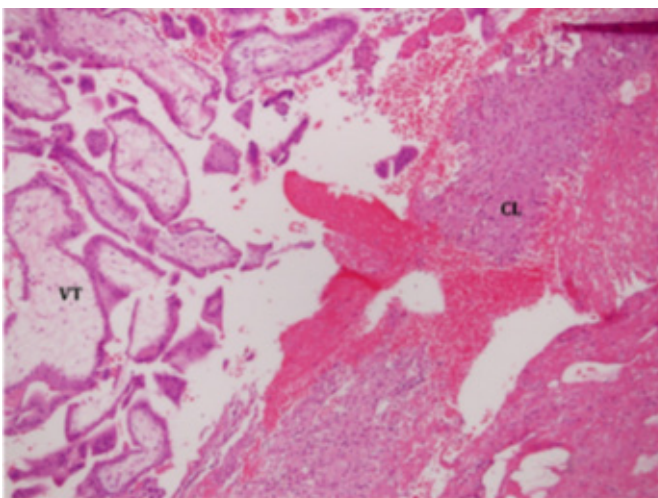
A 18 year old female patient was admitted with right lower abdominal pain for 1 week. It is about 10 week after her last menses. Her previous menstrual cycles were regular. The menstrual with average flow and without dysmenorrhea. Her medical history was negative. On examination, she had no pallor, a pulse of 80/min, and blood pressure of 100/70 mmHg. The left adnexal region was not palpable. Whereas there was tenderness in the right iliac fossa. Vaginal examination showed normal uterine size. There is no cervical motion tenderness. On examination, serum hCG was 10368 mU/L, Hb% was 10.6g%. The transvaginal ultrasonography showed an empty uterine cavity, a hyperechoic shadow in the right adnexa like for a yolk sac. And the free fluid was observed in the pouch of Douglas. The emergency laparoscopic exploration revealed a normal uterus with both normal fallopian tubes. The left ovary was normal, while the right ovary was enlarged with oozing of blood from the surface of an orange-red mass. The mass is 2\*3cm. Blood in the pouch of Douglas was observed. It is about 300ml. Ovarian wedge resection was carried out using scissors and bipolar diathermy for the coagulation of the bed of the ovarian pregnancy. The postoperative period was uneventful. The patient was discharged fourth day after the operation. The pathological histopathological examination revealed a villous structure embedded in the ovarian tissue, which was confirmatory of primary ovarian pregnancy. The serum hCG levels gradually returned to normal. The patient had no complications after the operation (Figure 1-3).



**Figure 1:** Ultrasound showing an heterogenous mass 20 mm adjacent to the ovary (OEP, ovarian ectopic pregnancy; Ov, ovary).



**Figure 2:** The laparoscopic view of left ovarian pregnancy. The tube is intact and the mass is adjacent to the ovary.



**Figure 3:** The pathological histopathological examination demonstrated villous tissue (VT, Left side of the image) adjacent to corpus luteum (CL, Right side of the image).

## 5. Discussion

The ovarian pregnancy is a rare type of ectopic pregnancy. But the pathogenesis remains unclear. Traditional risk factors for tubal pregnancy are not relevant in ovarian pregnancy, such as fallopian tube or pelvic inflammation [3]. The presumed risk factors for ovarian pregnancy include using of the intrauterine device (IUD), assisted reproductive techniques, concurrent endometriosis, pelvic adhesions, and intrauterine surgery. Especial The relationship between IUD and ovarian pregnancy

is established and recognized. The IUD use ranges from 57% to 90% of patients with a primary ovarian pregnancy [4]. The diagnostic criteria for ovarian pregnancy described by Spiegelberg include ovarian attachment to the uterus via the ovarian ligament, location of the gestational sac in or around the ovary, intact fallopian tube but with its fimbria and separated from the ovary, and ovarian tissue in the specimen on histological analysis [5,6]. In the clinical practice, the ovarian pregnancy is difficult to distinguish from ovarian corpus luteum rupture with tubal pregnancy abortion. The clinical manifestations of ovarian pregnancy are similar to those of tubal EP. The symptoms include menopause, abdominal pain, and vaginal bleeding. The clinical symptomatology of ovarian pregnancy makes preoperative diagnosis hardly impossible. Just as our case, She was diagnosed in laparoscopy. In our department the most of the patients were treated because of abdominal pain and intraperitoneal hemorrhage because of ovarian pregnancy [7,8]. The diagnosis of ovarian pregnancy is established. The ovarian pregnancy can be managed through conservative or surgical treatments. Conservative treatment includes expectant treatment and medication. Because of the lack of muscle tissue around ovarian pregnancy lesions and abundant ovarian blood supply, MTX treatment can destroy the villi, then the blood clot formed after embryo sac necrosis increases the volume of the lesion, which may accelerate the rupture and lead to serious intra-abdominal bleeding. The laparoscopy has become the standard in the management of hemodynamically stable patients with ovarian pregnancy. In the operation, resection of the ectopic pregnancy while retention of the ovary is a reasonable surgical objective, especial in patients desiring future fertility. The resection most commonly involves an ovarian wedge resection to remove as little normal ovarian tissue as possible. In the operation, we used laparoscopic scissors to separate and remove the pregnancy lesions. Then sutured the ovaries with an absorbable suture [9,10].

## 6. Conclusion

The ovarian pregnancies are rare. The unruptured ovarian pregnancies are rarer. The unruptured case herein demonstrated the possibility of an unruptured and viable ovarian pregnancy, which can help us better understand the clinical manifestations, imaging findings, and laparoscopic morphology of ovarian pregnancy. Once the ovarian pregnancy is ruptured, a massive hemorrhage can lead to severe complications. Understanding the clinical characteristics of an unruptured ovarian pregnancy can allow early detection and implementation of an active treatment to reduce the risk of serious complications. More definitive diagnosis of ovarian pregnancies must be reported in order to better understand the condition and identify optimal preoperative examination methods and management strategies.

## Reference

1. Butts JB, Phaneuf RJ. Ovarian pregnancy. *N Engl J Med.* 1960; 263: 1077-8.
2. Odejimi F, Rizzuto MI, Macrae R, Olowu O, Hussain M. Diagnosis and laparoscopic management of 12 consecutive cases of ovarian

# Annals of Clinical and Medical Case Reports

---

- pregnancy and review of literature. *J Minimally Invasive Gynecol.* 2009; 16(3): 354-9.
3. Choi HJ, Im KS, Jung HJ, Lim KT, Mok JE, Kwon YS. Clinical analysis of ovarian pregnancy: a report of 49 cases. *Eur J Obstet Gynecol Reprod Biol.* 2011; 158(1): 87-9.
  4. Goyal LD, Tondon R, Goel P, Sehgal A. Ovarian ectopic pregnancy: A 10 years' experience and review of literature. *Iran J Reprod Med.* 2014; 12(12): 825-30.
  5. Kirk E, Bottomley C, Bourne T. Diagnosing ectopic pregnancy and current concepts in the management of pregnancy of unknown location. *Hum Reprod Update.* 2014; 20(2): 250-61.
  6. Gupta N, Gupta A, Onyema G, Pantofel Y, Ying SC, Garon JE, Lampley C, Blankstein J. Accurate preoperative diagnosis of ovarian pregnancy with transvaginal scan. *Case Rep Obstet Gynecol.* 2012; 2012: 934571.
  7. Begum J, Pallavee P, Samal S. Diagnostic dilemma in ovarian pregnancy: a case series. *J Clin Diagn Res.* 2015; 9(4): QR01-03.
  8. Zhu Q, Li C, Zhao WH, Yuan JJ, Yan MX, Qin GJ, et al. Risk factors and clinical features of ovarian pregnancy: A case-control study. *BMJ Open* 2014, 4(12). e006447.
  9. Thanasa E, Thanasa A, Gerokostas EE, Kamaretsos E, Koutalia N, Kontogeorgis G, et al. Rupture of ectopic ovarian pregnancy accompanied by massive intra-abdominal bleeding and disorder of the coagulation mechanism: A rare and life-threatening obstetric complication. *Cureus* 2022; 14 (8): e28112.
  10. Sergent F, Mauger-Tinlot F, Gravier A, and Verspyck, E. Ovarian pregnancies: Reevaluation of diagnostic criteria. *J. Gynecol. Obstet. Biol. Reprod.* 2002; 31: 741.