

## Severe Bradycardia That Lead to Mobitz Type Two Heart Block in A Pregnant African American Female Who Got Infected with Covid-19

Aubin Sandio\*, Christina Reji, Smart Asare, Sanjana Ramakrishnan, Patrick Raymond Cadet, Cecile Koumou, Stephen Dada, Mayowa Apata and Donald Tynes

Internal Medicine Department, Detroit Medical Center, USA

### \*Corresponding author:

Aubin Sinclair Sandio,  
Internal Medicine Department, Detroit Medical Center,  
USA, E-mail: [asandio@med.wayne.edu](mailto:asandio@med.wayne.edu)

Received: 11 Apr 2022

Accepted: 09 May 2022

Published: 14 May 2022

J Short Name: ACMCR

### Copyright:

©2022 Aubin Sandio. This is an open access article distributed under the terms of the Creative Commons Attribution License, which permits unrestricted use, distribution, and build upon your work non-commercially.

### Citation:

Aubin Sandio, Severe Bradycardia That Lead to Mobitz Type Two Heart Block in A Pregnant African American Female Who Got Infected with Covid-19. *Ann Clin Med Case Rep.* 2022; V9(3): 1-4

## 1. Abstract

Impact of COVID-19 on certain patient populations have been described extensively in several studies. However, the impact of COVID-19 on pregnant patients and how they can be safely managed still remains elusive. We report a case of a 30-year-old African American pregnant woman who presented with a six (6) day history of cough with whitish expectorant, exertional shortness of breath and diffuse generalized body aches. She was admitted and managed with a bolus dose of Remdesivir, however on day eight (8) she had symptoms of dyspnea, chest pain, fatigue and became diaphoretic and pale. Physical exam revealed severe bradycardia and EKG studies showed second degree Mobitz type 2 heart block. The purpose of this study is bringing to clinicians' attention the possibility of developing severe bradycardia within few days' management of covid-19 symptoms particularly in pregnant African American females treated with Remdesivir. If patient complains of chest pain and bradycardia particularly after being diagnosed of covid-19 infection and properly managed, EKG studies should be promptly ordered to rule out any cardiac issues. Electrolyte studies should be also ordered. This patient had normal electrolyte levels.

## 2. Introduction

Worldwide, women of reproductive age (15-44 years) consist of 25.4% of all reported cases [1,2]. In the US (as of June 2020) they accounted for 21% of all cases reported to the US Center for Disease Control and Prevention (CDC), 9% of whom were pregnant. The rates of critical or severe COVID among pregnant women was

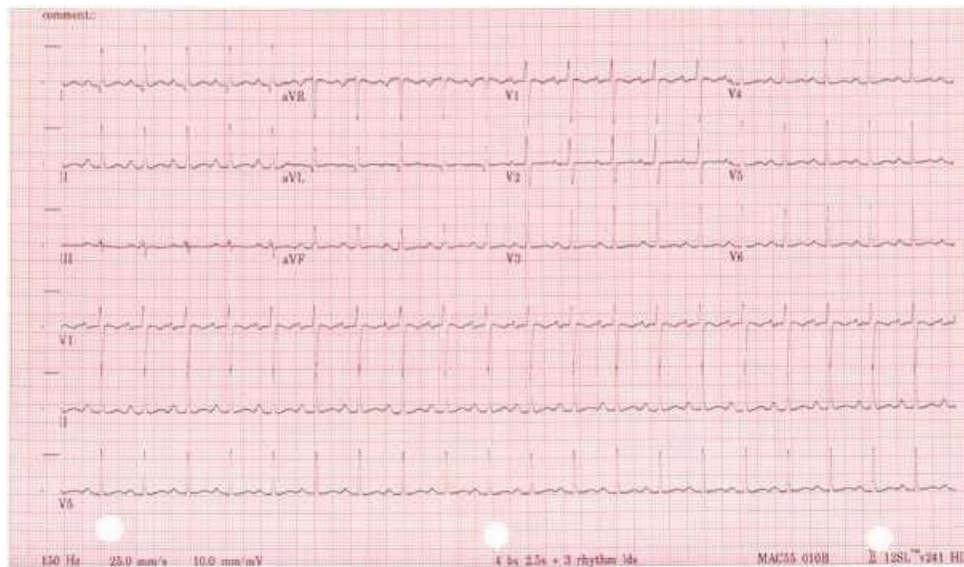
9-14%, similar to those of non pregnant adults. However, after adjusting for age, comorbidities, race and ethnicity, pregnant women were more likely to be hospitalized and ended to the intensive care unit (ICU) and require invasive mechanical ventilation (IMV) [3]. As per current COVID-19 treatment guidelines, the mainstay of treatment of non-hospitalized patients with mild to moderate COVID include SARS-CoV-2 antibodies Bamlanivimab or Casirivimab plus Imdevimab. Treatment of hospitalized patients not requiring oxygen is symptomatic and does not include steroids. Treatment of hospitalized patients requiring supplemental oxygen (not via extracorporeal membrane oxygenation (ECMO)), IMV, non-invasive ventilation (NIV), high flow devices) and consists of Dexamethasone and Remdesivir. And finally, those who were hospitalized and required ECMO, IMV, NIV, high flow devices warrant only use of Dexamethasone. The strength of these recommendations is largely based on expert opinion and a few randomized trials or sub group analysis of randomized trials [5]. Despite increased vulnerability of pregnant women to COVID-19, they are almost universally excluded from drug studies [4].

## 3. Case Presentation

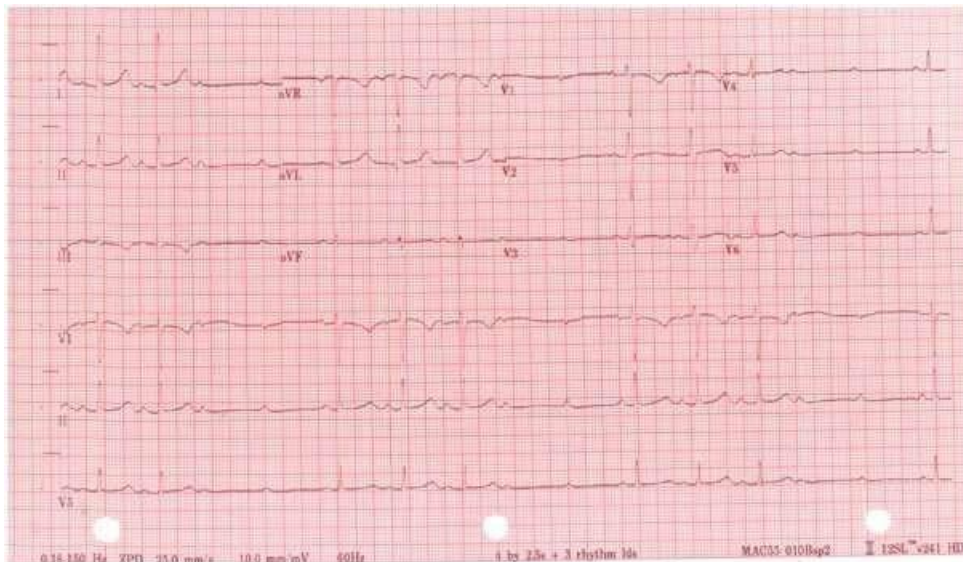A 30-year-old African American woman, pregnant at 33 weeks 3 days (G5P3L3A1) presented to the emergency department (ED) with a 6-day history of cough with whitish expectoration, diffuse generalized body aches and exertional shortness of breath (SOB). Her past medical history was significant for mild intermittent asthma, obesity, recurrent genital herpes simplex. She was on acyclovir

prophylaxis. She also recently got gonorrhoea infection for which she was treated with IM ceftriaxone 2 weeks prior to admission. She was admitted in the hospital and was diagnosed with COVID 19 active infection. They had recommended Bamlanivimab but did not have slots for the same. As she had no resting or exertional hypoxia, and improved symptomatically with fluids, albuterol and Pulmicort, she was sent home the same day to return to the hospital 3 days later for the infusion. Over time, symptoms did not abate, and she returned to the hospital and received Bamlanivimab 700 mg IV. She was tachycardic at this time. However, all other vitals were stable. She was sent home on Fluticasone and Albuterol inhaler and Guifenesin cough syrup. Symptoms continued to persist over the next 2 days and she arrived at our hospital. While still admitted at the ED, blood pressure (BP):100/60, heart rate (HR):120 bpm, respiratory rate (RR): 20/min, saturation (SpO2): 94% on RA, afebrile. Her BP started to drop, and she was given 3 litres of Normal Saline (NS) boluses. Despite this, Norepinephrine (NE) had to be started at a rate of 0.1mcg/kg/min. She also started desaturating and had to be started on a non-rebreather mask (NRBM) at 15L/min. Chest X-Ray (CXR) showed bilateral pneumonia. D-Dimer:5.22, CRP: 68.5, Ferritin 15.9. She tested positive for COVID again. Lactic acid: 0.8. Other labs including Complete

Blood Count (CBC), Complete metabolic panel (CMP), and Electrolytes were normal. CTPE showed numerous patchy opacities bilaterally (B/L) in a peripheral distribution. She was admitted to the Intensive care unit (ICU) and was started on Dexamethasone 6mg PO QD, Enoxaparin 40 mg Q12H, 100ml/hr of NS. She also received single doses of IV Ceftriaxone 1-gram QD and Azithro IV while at the ED. Initially as she was on NRBM, she did not qualify for Remdesivir as per hospital protocol. However, she was able to de-escalate to the nasal cannula on the same day. At this point, she met institutional guidelines for Remdesivir and was given her first loading dose of 200 mg IV. One hour after infusion, she developed a new second degree heart block (HB): Mobitz type 2. Remdesivir was held. Routine blood test showed that the electrolyte panel was normal. She was asymptomatic and continued to go in and out of normal sinus rhythm (NSR) and Mobitz type 2 with a lowest recorded HR or 50 bpm. An electrophysiology (EP) consultation was placed. Review of telemetry showed sinus rhythm, with episodes of 3:1 Conduction, no significant increase in PR interval before dropped beat. Dropped beat was subsequently followed by junctional rhythm and sinus conduction. By the next morning, her rhythm was showing Mobitz type 1 pattern. Through the whole ICU admission, her pressor requirements had not varied.

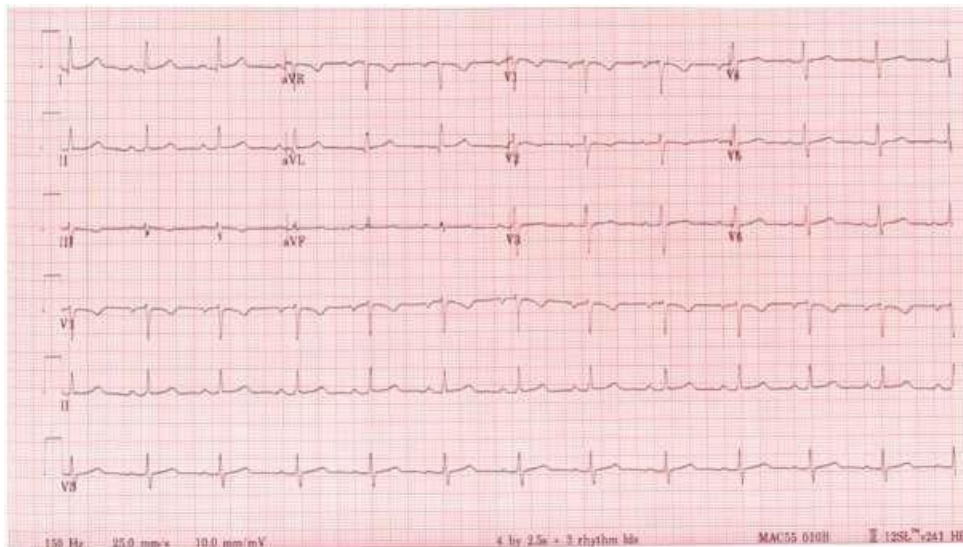


**Figure 1:** EKG showing normal sinus rhythm with ventricular rate 77bpm and normal QT/QTc Interval 388/439 ms.



**Figure 2:** EKG during admission.

#### 4. Discussion



**Figure 3:** EKG few days after discontinuation of Remdesivir.

The rates of severe COVID -19 in pregnant women is similar to those of non- pregnant adults, requiring hospitalization and possible ICU management. As per current guidelines, Remdesivir with Dexamethasone is recommended for hospitalized patients requiring supplemental oxygen. Remdesivir is a broad- spectrum antiviral drug and is the only FDA-approved drug for the management of COVID-19 patients. The active form of remdesivir acts as a nucleoside analog and inhibits the RNA-dependent RNA polymerase (RdRp) of coronaviruses including SARS-CoV-2 (5). The treatment guidelines are largely based on a few randomized trials or sub group analysis of randomized trials. However, pregnant population have been excluded from various studies. This case describes about a pregnant patient who suffered a serious cardiac side effect of Remdesivir and highlights the need for continuous EKG evaluation for pregnant patients. There are only a few studies

that focus on the effects of Remdesivir on cardiovascular system (3,15-17, 21-24). In a recent study, 302 cardiac effects were reported including 94 bradycardias, where (31%) of the 2603 reports were patients covid-19 who were prescribed remdesivir. Most of the 94 reports were serious (75, 80%), and in 16 reports (17%) evolution was fatal (29). According to this study, the use of remdesivir was associated with an increased risk of reporting bradycardia (ROR 1.65; 95% CI 1.23-2.22), compared with hydroxychloroquine, lopinavir/ritonavir, tocilizumab or glucocorticoids. Bradycardia and EKG changes mentioned in this study is consistent with the findings in this case report. Our 30-year-old G5P3L3A1 at 33 weeks gestation, developed bradycardia within two days with administration of 200 mg IV loading dose of Remdesivir. Rhythm analysis revealed Mobitz type 2 HB after which Remdesivir was held. However, she kept going in and out of NSR and Mobitz type 2 for the next 6-7 hours just after day 2. It is important to note that



she was administered a single dose of Azithromycin IV while at the ED on the same day. Azithromycin is well known to cause QT prolongation and it may have contributed to the EKG changes. To add to the perplexity, the impact of SARS-CoV-2 in pregnancy remains to be determined (4) and cases of myocarditis presenting with AV blocks in patients with COVID-19 have been reported (31,32).

## 5. Conclusion

The purpose of this case report is to sensitize clinicians to the need for close EKG monitoring for COVID patients on Remdesivir, especially during pregnancy. Owing to the fact that there is a need for more corroborative evidence of the effect of COVID-19 and its treatment regimen on pregnancy, researchers should be urged to consider inclusion of pregnant women and other underrepresented groups in randomized controlled trials to ensure positive patient outcomes.

## References

1. Yuki, Koichi, Miho Fujiogi, Sophia Koutsogiannaki. "COVID-19 Pathophysiology: A Review." *Clinical Immunology* (Orlando, Fla. 2020; 108427).
2. N d. <https://data.unwomen.org/resources/covid-19-emerging-gender-data-and-why-it-matters>.
3. Burwick, Richard M, Sigal Yawetz, Kathryn E, Stephenson, Ai-Ris Y, et al. "Compassionate Use of Remdesivir in Pregnant Women with Severe Covid-19." *Clinical Infectious Diseases: An Official Publication of the Infectious Diseases Society of America*, October. 2020.
4. Wastnedge, Elizabeth A N, Rebecca M, Reynolds, Sara R, van Boeckel. "Pregnancy and COVID-19." *Physiological Reviews* 101, no. 2021; 303-18.
5. Kokic, Goran, Hauke S. Hillen, Dimitry Teginov, Christian Diemann. "Mechanism of SARS-CoV-2 Polymerase Stalling by Remdesivir." *Nature Communications*. 2021; 279.
6. Grein, Jonathan, Norio Ohmagari, Daniel Shin, George Diaz, Erika Asperges, et al. "Compassionate Use of Remdesivir for Patients with Severe Covid-19." *New England Journal of Medicine* 382, no. 2020; 24: 2327-36.
7. PK and Safety of Remdesivir for Treatment of COVID-19 in Pregnant and Non-Pregnant Women in the US," n.d.
8. Anupam K Gupta. Cardiac Adverse Events with Remdesivir in COVID-19 Infection.
9. Grein J, Ohmagari N, Shin D. Compassionate use of Remdesivir for patients with severe Covid-19 . *N Engl J Med*. 2020; 382: 2327-2336.
10. Humeniuk R, Mathias A, Cao H. Safety, tolerability, and pharmacokinetics of Remdesivir, an antiviral for treatment of COVID-19, in health subjects. *Clin Transl Sci*. 2020; 13: 896-906.
11. Javorac D, Grahovac L, Manic L. An overview of the safety assessment of medicines currently used in the COVID-19 disease treatment. *Food Chem Toxicol*. 2020; 144: 111639.
12. Aggarwal G, Henry BM, Aggarwal S, Bangalore S. Cardiovascular safety of potential drugs for the treatment of Coronavirus disease 2019. *Am J Cardiol*. 2020; 128: 147-150.
13. Barkas, Fotios, Chrysoula-Paraskevi Styla, Aris Bechlioulis, Haralampos Milionis, Evangelos Liberopoulos. "Sinus Bradycardia Associated with Remdesivir Treatment in COVID-19: A Case Report and Literature Review." *Journal of Cardiovascular Development and Disease*. 2021.
14. Gubitosa, James C, Parul Kakar, Christine Gerula, Hernando Noss, Diana Finkel, et al. "Marked Sinus Bradycardia Associated with Remdesivir in COVID-19: A Case and Literature Review." *JACC. Case Reports* 2, no. 2020; 2260-64.
15. Gupta, Anupam K, Barbara M Parker, Vikash Priyadarshi, John Parker. "Cardiac Adverse Events with Remdesivir in COVID-19 Infection." *Cureus*, October. 2020; 24.
16. Musa A, Pendi K, Hashemi A. Remdesivir for the treatment of COVID-19: a systematic review of the literature. *West J Emerg Med*. 2020; 21: 737-741.
17. Liang C, Tian L, Liu Y. A promising antiviral candidate drug for the COVID-19 pandemic: a minireview of remdesivir. *Eur J Med Chem*. 2020; 201: 112527.
18. Humeniuk R, Mathias A, Cao H. Safety, tolerability, and pharmacokinetics of Remdesivir, an antiviral for treatment of COVID-19, in health subjects. *Clin Transl Sci*. 2020; 13: 896-906.
19. Tchesnokov, Egor P, Joy Y, Feng, Danielle P. "Mechanism of Inhibition of Ebola Virus RNA-Dependent RNA Polymerase by Remdesivir." 2019; 11.
20. VigiAccessTM, n.d. <http://www.vigiaccess.org>.
21. Touafchia, Anthony, Haleh Bagheri, Didier Carrié, Geneviève Durrieu, Agnès Sommet, et al. "Serious Bradycardia and Remdesivir for Coronavirus 2019 (COVID-19): A New Safety Concerns." *Clinical Microbiology and Infection: The Official Publication of the European Society of Clinical Microbiology and Infectious Diseases*, February. 2021.
22. Ashok, Vishnu, and Wei Ian Loke. "Case Report: High-Grade Atrioventricular Block in Suspected COVID-19 Myocarditis." *European Heart Journal. Case Reports* 4, no. F11. 2020; 1-6.
23. MonmeneuJose V, Mafe Eloy Dominguez, SolerJorge Andres, Perez Bruno Ventura, Caravaca Javier Solsona , Torres Ricardo Broseta, et al . Subacute perimyocarditis in a young patient with COVID-19 infection. *Eur Heart J Case Rep*. 2020.
24. Ruan Q, Yang K, Wang W, Jiang L, SongJ. Clinical predictors of mortality due to COVID-19 based on an analysis of data of 150 patients from Wuhan, China. *Intensive Care Med*. 2020; 46: 846-848.