

Successful Rechallenge of Hepatocellular Carcinoma with Atezolizumab and Bevacizumab Following Disease Progression

Abraham S* and Samson A

Leeds Institute of Medical Research, University of Leeds, Leeds, United Kingdom

*Corresponding author:

Shalin Abraham,
Leeds Institute of Medical Research, University of
Leeds, Leeds, United Kingdom, Tel: +44(0)113 343
8449; E-mail: s.e.abraham@leeds.ac.uk and
a.samson@leeds.ac.uk

Received: 01 Jan 2023

Accepted: 13 Feb 2023

Published: 20 Feb 2023

J Short Name: ACMCR

Copyright:

©2023 Abraham S. This is an open access article distributed under the terms of the Creative Commons Attribution License, which permits unrestricted use, distribution, and build upon your work non-commercially

Keywords:

Hepatocellular carcinoma; Immune checkpoint inhibitors; Anti-Angiogenic agent; Disease progression; Risk stratification

Citation:

Abraham S, Successful Rechallenge of Hepatocellular Carcinoma with Atezolizumab and Bevacizumab Following Disease Progression. Ann Clin Med Case Rep. 2023; V10(12): 1-4

1. Abstract

Systemic therapies to treat Hepatocellular Carcinoma (HCC), a cancer with traditionally poor prognosis, have greatly advanced in the last five years with the advent of immunotherapies. The immune checkpoint inhibitor atezolizumab and anti-angiogenic agent bevacizumab combination therapy is now recommended as first line treatment for unresectable HCC. Bevacizumab is associated with an increased risk of severe variceal or mucosal bleeding. We present a remarkable case of a patient with multifocal HCC being treated with combination atezolizumab and bevacizumab therapy. The patient experienced complete response to combination therapy. He then suffered a life-threatening gastrointestinal bleed secondary to *Helicobacter pylori*-associated gastric ulceration. Bevacizumab was interrupted for a period of 6 months, with continuing atezolizumab monotherapy. Serial endoscopies demonstrated re-epithelialisation of the ulcer. Following disease progression, bevacizumab was recommenced in combination with atezolizumab, leading to consequent partial response. This case highlights the synergistic efficacy of combination atezolizumab and bevacizumab therapy and the importance of risk stratification for patients with significant bleeding events on bevacizumab to guide the period of drug interruption and timely rechallenge with combination therapy.

2. Introduction

Hepatocellular Carcinoma (HCC) has the highest incidence of primary liver cancers and is a cause of significant morbidity and mortality worldwide. Unfortunately, HCC is often diagnosed at

advanced stage, where surgical or interventional radiological management is not possible and systemic therapies must be used to control disease [1]. Recently there have been great developments in the field of systemic therapies for HCC. The multikinase inhibitors sorafenib or lenvatinib were previously approved for the treatment of unresectable HCC [2,3]. Recently, the pivotal phase 3 study, IM Brave 150 demonstrated that the Programmed Cell Death Ligand 1 (PD-L1) inhibitor atezolizumab and Anti-Vascular Endothelial Growth Factor (VEG-F) agent bevacizumab, resulted in superior overall and progression free survival in comparison to sorafenib and have since been approved as first line therapy for treatment in patients with unresectable HCC [4]. As with other anti-cancer therapies, these are not without side effects. Bevacizumab is associated with increased risk of severe mucosal bleeding including gastrointestinal bleeding [5]. Risk factors for the development of HCC include liver cirrhosis because of chronic hepatitis B or C, chronic alcohol intake or non-alcoholic fatty liver diseases. Increased portal venous pressure in patients with cirrhosis leads to portal hypertension, predisposing patients to oesophageal and gastric varices, which are at risk of bleeding. Furthermore, patients with cancer are at increased risk of venous thrombosis which can be treated with therapeutic anticoagulation [6]. It is therefore paramount to understand the clinical progression of HCC patients taking atezolizumab and bevacizumab, with factors that may predispose to increased mucosal bleed risk. We present the unique case of an 81-year-old gentleman with multifocal hepatocellular carcinoma who experienced complete radiological response on atezolizumab/ bevacizumab combination therapy. Bevacizumab was

paused following a significant upper gastrointestinal bleed secondary to peptic ulcer, with continuation of single agent atezolizumab. Upon cancer progression, bevacizumab was restarted, resulting in a further radiological response. To our knowledge, this is the first case report to document a response of this kind following pause in combination therapy.

3. Case Report

We present the case of an 81-year-old gentleman with multifocal HCC spread across the right lobe of the liver. He underwent a surgical resection in 2013 and had four episodes of trans-arterial chemoembolization between 2018 and 2019. He has a significant past medical history of atrial fibrillation, diet-controlled type 2 diabetes mellitus and hypertension. Medication history on diagnosis included atorvastatin, candesartan, bisoprolol, bendroflumethiazide and full dose edoxaban (60 mg once daily).

He re-presented with unresectable bi-lobar multi-focal HCC, with TNM staging T2 N0 M0 and no macrovascular invasion. His underlying liver function was good with Child-Pugh score A5 and alpha-fetoprotein level of 3236 Ku/L. His Eastern Cooperative Oncology Group (ECOG) performance status was 0. His clinical examination was unremarkable. He commenced atezolizumab and bevacizumab in September 2020 and Computed Tomography (CT) scan in December 2020 demonstrated a good partial response, with no side effects of note to treatment. In February 2021, no definite viable tumour was identified on CT scan. Unfortunately, in March 2021 he developed melaena with a haemoglobin drop from

135 g/L to 83 g/L suggestive of upper gastrointestinal bleed. Upper gastrointestinal endoscopy revealed a 10 mm gastric ulcer in the incisura with visible vessel of Forrest IIa classification, treated with adrenaline injection and argon plasma coagulation with high dose proton pump inhibitor treatment for 3 months. Consequently, bevacizumab was stopped and atezolizumab monotherapy continued. A repeat upper gastrointestinal endoscopy in May 2021 showed the previously seen ulcer with no obvious visible vessel from which biopsies were taken, a further small fundal ulcer and grade 1 gastro-oesophageal varices. Ulcer biopsies revealed *Helicobacter pylori* (*H. pylori*) infection and he was treated with amoxicillin and clarithromycin eradication therapy. Repeat upper gastrointestinal endoscopy in July 2021 showed almost complete re-epithelialization of the gastric ulcer (Figure 1).

In August 2021, unfortunately CT scan demonstrated two enlarging liver and bone lesions, not suitable for stereotactic body radiotherapy. Bevacizumab was therefore restarted in October 2021 in combination with the ongoing atezolizumab, 6 months after the previous significant gastrointestinal bleed. In March 2022, CT scan found a T7 spinal metastatic lesion was encroaching on the spinal canal which was treated with one fraction of external beam radiotherapy after a short break from systemic therapy. His latest CT scan in September 2022 has shown stabilisation of all the bone lesions and reduced enhancement in the segment 8 liver lesion, indicating partial response to rechallenge combination treatment (Figure 2).

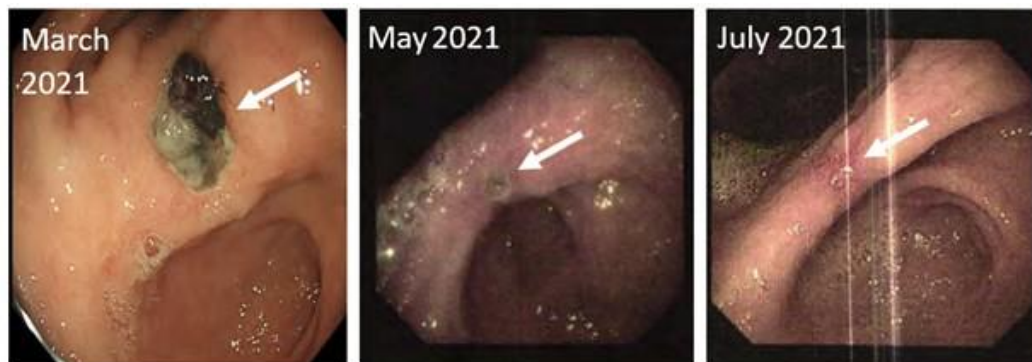
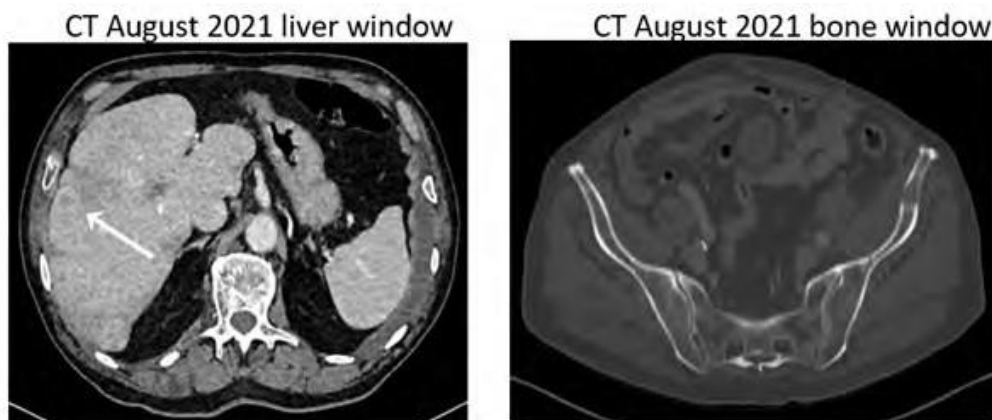


Figure 1: Serial upper gastrointestinal endoscopies showing gastric ulcer identified with arrow and the process of re-epithelialisation over 5 months.



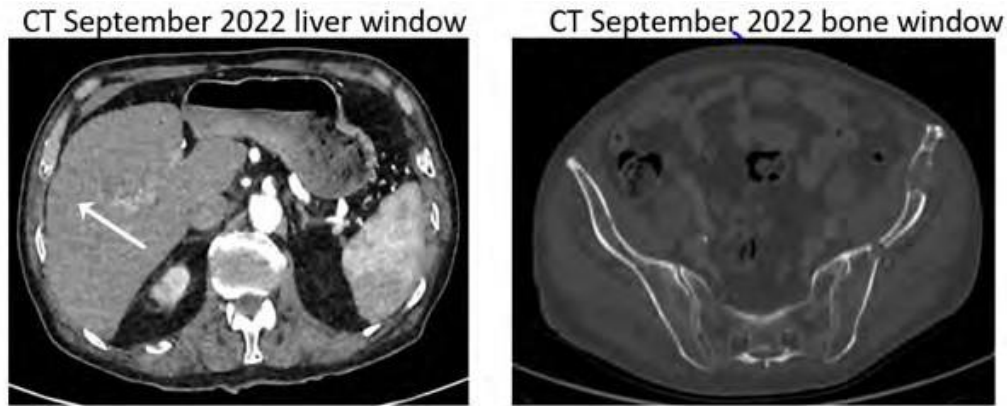


Figure 2: CT images August 2021 and September 2022 of liver and iliac bones demonstrating stable bony metastatic disease and reduced enhancement of segment 8 liver lesion.

4. Discussion

Bevacizumab is a humanised monoclonal antibody which blocks binding of VEG-F to the receptors on vascular endothelial and other cells to inhibit angiogenesis and tumour. It was the first anti-angiogenic agent to be approved by the Food and Drug Administration (2004) and European Medicines Agency (2005) [7]. VEG-F is a cytokine which is a key regulator of angiogenesis. Angiogenesis is the formation of new blood vessels by remodelling and expansion of primary blood vessels. As tumours grow, hypoxia, glucose deprivation and mechanical stress lead to transcription of hypoxia-inducible genes such as VEG-F, known as the ‘angiogenic switch’ [8]. This induces neovascularisation, increases vascular permeability and additionally VEG-F has been shown to have increased expression in tumour cells [9,10].

VEG-F also has immunosuppressive properties. For example, autocrine signalling independent of the VEG-F receptor within regulatory T cells (Tregs), which suppress the antitumor immune response, results in Tregs being guided into tumours by VEG-F, as well as promoting release of immunosuppressive cytokines [11]. VEG-F mobilises Tumour-Associated Macrophages (TAMs), and results in polarisation to the M2 phenotype with immunosuppressive and pro-angiogenic properties, which promotes tumour growth. VEG-F activates Myeloid-Derived Suppressor Cells (MDSCs), which also release VEG-F. VEG-F also inhibits dendritic cell maturation and antigen presentation, reducing activation of CD8+ T cells. As a result, VEG-F creates an immunosuppressive tumour environment inhibiting T cell function. The administration of bevacizumab reverses this environment from immunosuppressive to immunostimulatory. When VEG-F inhibitors are combined with PD-L1 inhibitors there is effective priming of T cells; normalisation of tumour vasculature to encourage T cell infiltration into the tumour site; inhibition of the Tregs, TAMs and MDSCs; and finally PD-L1 inhibition promotes enhanced T-cell attack on tumour cells [12]. In this patient, the cessation of bevacizumab following gastrointestinal bleeding would likely have resulted in the re-establishment of Treg and MDSC activities, resulting in cancer

progression. This report highlights the synergistic efficacy of combination PD-L1 and VEG-F inhibition, with the observance of a further radiological response following the recommencement of bevacizumab therapy.

Given the action of bevacizumab on angiogenesis, the link between bevacizumab and increased bleeding is perhaps unsurprising. Bevacizumab therapy can result in two distinct patterns of bleeding. The first is minor haemorrhage, most commonly grade 1 epistaxis. The second pattern is one of major haemorrhage, which can be fatal in some cases, including gastrointestinal bleed, haemoptysis, vaginal bleed, or brain haemorrhage. A meta-analysis of adverse events of bevacizumab in 13 randomised controlled trials showed that the bevacizumab group had a higher risk for any severe adverse event, particularly a fourfold higher risk for epistaxis and gastrointestinal haemorrhage or perforation and a threefold higher risk for any bleeding events [7]. The mechanism underlying bevacizumab-related bleeding has not been fully elucidated, however it is likely related to inhibition of VEG-F induced endothelial cell survival and reduction in vascular integrity. Life-threatening bleeds are more likely to be caused by damage of major vessel walls through tumour erosion, necrosis, or cavitation [13].

Patients at high risk of bleeding were excluded from clinical trials of patients in hepatocellular carcinoma, so guidance is based on observational data. Current recommendation is that screening for gastrointestinal varices is recommended within six months of initiating bevacizumab in patients with hepatocellular carcinoma [14]. There is a dearth of clinical data to support treatment with bevacizumab within six months of variceal bleed or in those with partially or untreated varices. Furthermore, there has shown to be a positive association between *Helicobacter pylori* (*H. pylori*) infection and development of hepatocellular carcinoma, particularly with hepatitis C virus co-infection, although causation has not been proven yet [15].

We present a remarkable case of a patient who suffered a gastrointestinal bleed secondary to *H. pylori* associated peptic ulcer disease, with co-existing grade 1 varices while on both the anticoagu-

lant edoxaban and bevacizumab, who then was able to subsequently restart bevacizumab following a 6-month cessation. The patient has had subsequent partial response to combined atezolizumab/bevacizumab therapy. Limitations of this case include the lack of pre-treatment endoscopic screening due to COVID-19 pandemic restrictions, however this patient was at low risk for variceal disease due to preserved underlying liver function. This case highlights the importance of re-commencing bevacizumab where this is possible in patients where it has been paused for the management of toxicity. The case also emphasises the role that serial endoscopic surveillance plays in monitoring of high-risk bleeding lesions in hepatocellular carcinoma. We recommend the development of an approach to risk stratify HCC patients following severe upper gastrointestinal bleed, which should include co-existing oral anticoagulation, evidence of varices and grade, presence of portal vein tumour invasion and the presence of *H. pylori*, to guide clinical decision making regarding the period of cessation of bevacizumab therapy.

5. Disclosures

Competing Interests

Dr Adel Samson has received consultancy fees from Roche.

Funding

Dr Shalin Abraham is a National Institute of Health Research (NIHR) Academic Clinical Fellow.

Dr Adel Samson is a Cancer Research UK (CRUK) Clinician Scientist Fellow.

Acknowledgement

The patient Leeds Teaching Hospitals NHS Trust.

References

1. McGlynn KA, Petrick JL, El-Serag HB. Epidemiology of Hepatocellular Carcinoma. *Hepatology*. 2021; 73 Suppl 1: 4-13.
2. Llovet JM, Ricci S, Mazzaferro V, Hilgard P, Gane E, Blanc JF, et al. Sorafenib in Advanced Hepatocellular Carcinoma. *New England Journal of Medicine*. 2008; 359(4): 378-90.
3. Kudo M, Finn RS, Qin S, Han KH, Ikeda K, Piscaglia F, et al. Lenvatinib versus sorafenib in first-line treatment of patients with unresectable hepatocellular carcinoma: a randomised phase 3 non-inferiority trial. *The Lancet*. 2018; 391(10126): 1163-73.
4. Finn RS, Qin S, Ikeda M, Galle PR, Ducreux M, Kim TY, et al. Atezolizumab plus Bevacizumab in Unresectable Hepatocellular Carcinoma. *N Engl J Med*. 2020; 382(20): 1894-905.
5. Leighl NB, Bennouna J, Yi J, Moore N, Hambleton J, Hurwitz H. Bleeding events in bevacizumab-treated cancer patients who received full-dose anticoagulation and remained on study. *Br J Cancer*. 2011; 104(3): 413-8.
6. Abdol Razak NB, Jones G, Bhandari M, Berndt MC, Metharom P, et al. Cancer-Associated Thrombosis: An Overview of Mechanisms, Risk Factors, and Treatment. *Cancers (Basel)*. 2018; 10(10): 380.
7. Geiger-Gritsch S, Stollenwerk B, Miksad R, Guba B, Wild C, Siebert U, et al. Safety of Bevacizumab in Patients with Advanced Cancer: A Meta-Analysis of Randomized Controlled Trials. *Oncologist*. 2010; 15(11): 1179-91.
8. Rosen LS. Clinical experience with angiogenesis signaling inhibitors: focus on vascular endothelial growth factor (VEGF) blockers. *Cancer Control*. 2002; 9(2 Suppl): 36-44.
9. Kabbinavar FF, Schulz J, McCleod M, Patel T, Hamm JT, Hecht JR, et al. Addition of bevacizumab to bolus fluorouracil and leucovorin in first-line metastatic colorectal cancer: results of a randomized phase II trial. *J Clin Oncol*. 2005; 23(16): 3697-705.
10. Herbst RS, Onn A, Sandler A. Angiogenesis and lung cancer: prognostic and therapeutic implications. *J Clin Oncol*. 2005; 23(14): 3243-56.
11. Goel HL, Mercurio AM. VEGF targets the tumour cell. *Nat Rev Cancer*. 2013; 13(12): 871-82.
12. Kudo M. Scientific Rationale for Combined Immunotherapy with PD-1/PD-L1 Antibodies and VEGF Inhibitors in Advanced Hepatocellular Carcinoma. *Cancers (Basel)*. 2020; 12(5): 1089.
13. Kamba T, McDonald DM. Mechanisms of adverse effects of anti-VEGF therapy for cancer. *Br J Cancer*. 2007; 96(12): 1788-95.
14. NICE. Evidence Atezolizumab with bevacizumab for treating advanced or unresectable hepatocellular carcinoma. Guidance. NICE; 2022.
15. Madala S, MacDougall K, Surapaneni BK, Park R, Kasi A, Girotra M, et al. Relationship between *Helicobacter pylori* and development of hepatocellular carcinoma: A systematic review and meta-analysis. *JCO*. 2021; 39(15_suppl): 4091-4091.