

Impactions in Orthodontics - A Review

Kulshrestha R¹, Shenava S², Mudaliar P³, Thomas R⁴, Matthew R⁵, Singh S⁶

¹Department of Orthodontics and Dentofacial Orthopaedics, Terna Dental College and Hospital, India

²Department of Orthodontics and Dentofacial Orthopaedics, Terna Dental College and Hospital, India

³Department of Orthodontics and Dentofacial Orthopaedics, Terna Dental College and Hospital, India

⁴Department of Orthodontics and Dentofacial Orthopaedics, Terna Dental College and Hospital, Maharashtra India

⁵Department of Orthodontics and Dentofacial Orthopaedics, Terna Dental College and Hospital, India

⁶Department of Orthodontics and Dentofacial Orthopaedics, Terna Dental College and Hospital, India

Volume 1 Issue 1 - 2018

Received Date: 4 June 2018

Accepted Date: 22 June 2018

Published Date: 27 June 2018

2. Keywords

Impaction; Canines; X-rays

1. Abstract

Tooth eruption involves the migration of the teeth from a nonfunctional position within the bone to a functional position in the jaw. In orthodontic practice, it is inevitable that one will encounter eruptive abnormalities such as impacted, ectopically erupting, transposed, congenitally missing, and supernumerary teeth. The treatment plans were developed to address these anomalies and soft tissue reactions to the teeth movements must be considered. This article presents an overview on cause and management of anomalies seen due to impaction.

3. Introduction

Eruptive anomalies are present in many routine orthodontic cases. The challenge in them is to diagnose them correctly and manage them in a way so as to maintain the esthetic and functional harmony of the stomatognathic system [1]. The orthodontist must know how to correct these anomalies rather than extracting the malposed tooth as this would lead to poor occlusion and loss of masticatory function [2]. This article presents an overview on various anomalies seen due to impaction in daily orthodontic practice along with step by step management of each.

Impaction

Impaction is defined as the total or partial lack of eruption of a tooth well after the normal age for eruption [3]. An impacted tooth may appear blocked by another tooth, bone, or soft tissue, or displaced so that it cannot erupt (**Figure 1**).

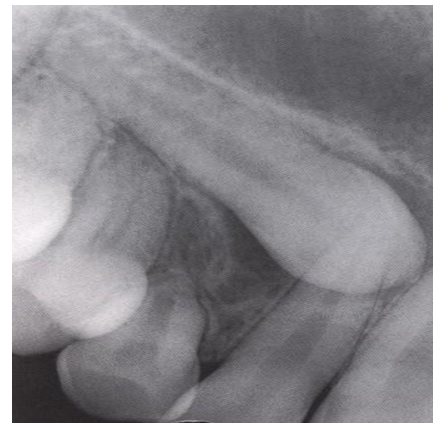


Figure 1: Impacted Canine.

Descending order of occurrence: maxillary and mandibular third molars, maxillary cuspids, second premolars, maxillary central incisors, mandibular cuspids, second molars, lateral incisors and first premolars.

4. Causes

Generalized causes include endocrine deficiencies, febrile diseases, and irradiation.

Localized causes (a) tooth size-arch length discrepancies, (b) prolonged retention or early loss of the deciduous canine, (c) abnormal position of the tooth bud, (d) the presence of an

*Corresponding Author (s): Rohit Kulshrestha, Department of Orthodontics and Dentofacial Orthopaedics, Terna Dental College and Hospital, India, E-mail: kulrohit@gmail.com

alveolar cleft, (e) ankylosis, (f) cystic or neoplastic formation, (g) dilaceration of the root, (h) iatrogenic origin (discussed earlier), and (i) idiopathic condition with no apparent cause [4]. Impaction may also be caused by

1. Primary causes:

- A. Rate of root resorption of deciduous teeth.
- B. Trauma of the deciduous tooth bud.
- C. Disturbances in tooth eruption sequence.
- D. Availability of space in the arch.
- E. Rotation of tooth buds.
- F. Premature root closure.
- G. cleft area in persons with cleft palate.

2. Secondary causes:

- A. Abnormal muscle pressure.
- B. Febrile diseases.
- C. Endocrine disturbances.
- D. Vitamin D deficiency.

Other pathological causes for impacted teeth are cysts, tumors and odontomes.

Studies have shown that the enamel organ of the developing teeth produces IL-1 α in response to the epidermal growth factor stimulation and this causes the follicular cells to produce CSF-1 suggesting that any follicular region may have the potential to remodel the bony crypt and that tooth impaction may be the aberrant activation of the dental follicle.

CSF-1 promotes the differentiation of monocytes, osteoclasts and macrophages, leading to bone resorption and formation around the developing tooth [5].

5. Clinical Evaluation

- (1) Delayed eruption of the permanent teeth and prolonged retention of the deciduous teeth beyond 14 to 15 years of age.
- (2) Absence of a normal labial bulge through intraoral palpation of the alveolar process
- (3) Presence of a palatal bulge.
- (4) Delayed eruption, distal tipping, or migration (splaying) of the adjacent teeth.

6. Radiographic Diagnosis of Impacted Teeth

Periapical Radiographs

It is possible to ascertain the crown or root resorption, root

formation and integrity, presence and size of the follicle, hard tissue obstruction such as odontomes as well as soft tissue lesions such as cysts. It is two dimensional and gives no information in buccolingual plane. To evaluate the position of the canine buccolingually, a second periapical film should be obtained by one of the following methods [6].

- a. Tube-shift technique or Clark's rule. Two periapical films are taken of the same area, with the horizontal angulation of the cone changed when the second film is taken (**Figure 2**).

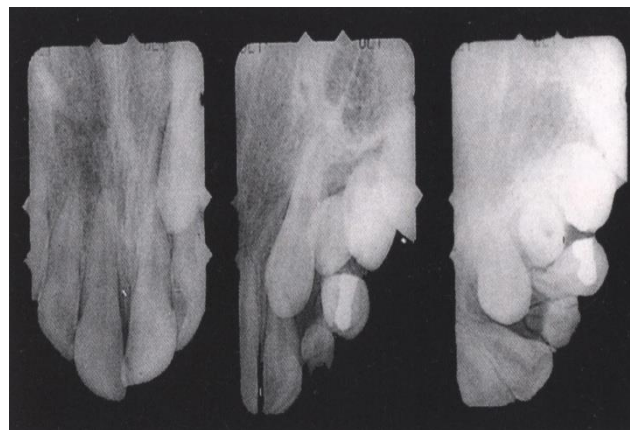


Figure 2: Cone shift technique.

If the object in question moves in the same direction as the cone, it is lingually positioned. If the object moves in the opposite direction, it is situated closer to the source of radiation and is therefore buccally located [7].

- b. Buccal-object rule. If the vertical angulation of the cone is changed by approximately 20° in two successive periapical films, the buccal object will move in the direction opposite the source of radiation. On the other hand, the lingual object will move in the same direction as the source of radiation [8].

Occlusal Radiographs

It depicts all the posterior and anterior standing teeth in cross section and provides buccolingual and mesiodistal information of the impacted teeth (**Figure 3**).

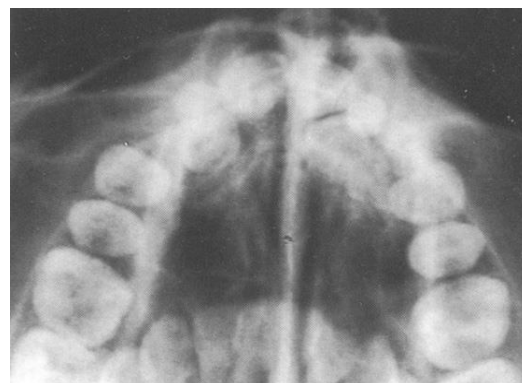

Figure 3: Occlusal Radiograph.

A palatally placed tooth will appear within this arc of small circles. An angled tooth will show up in its elliptical oblique cross section representing a tilted long axis.

Disadvantage: Relative height of the object cannot be made out.

Extraoral Radiographs

Panoramic radiographs, lateral and postero-anterior cephalograms. OPG gives a good scan of teeth in mesiodistal and vertical direction (**Figure 4**).

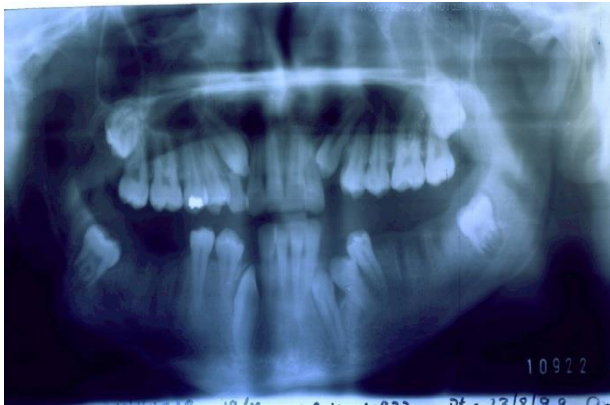

Figure 4: OPG with canine impactions.

Lateral cephalograms gives information regarding the vertical and anteroposterior position of the impacted tooth especially in cases of dilaceration. PA view defines the height and the buccolingual relationship [9]. By combining these, three dimensional view is obtained.

Three Dimensional Diagnosis of Tooth Position

Parallax Method: The palatal tooth will move in the same direction that the x ray tube has traveled from the first exposure [10].

Ct Scanning: By viewing serial radiographic slices of the maxilla, the relationship of the impacted tooth to the adjacent teeth in all three planes of space may be accurately assessed [11].

7. Treatment Options

1. Extraction of impacted tooth and movement of adjacent tooth in its position
2. Auto transplantation of impacted tooth
3. Prosthetic replacement of impacted tooth either with crown or with implant
4. Surgical exposure and placing a traction force to bring it into the arch (Guidance of eruption).

For guidance of eruption sufficient space is achieved by

1. Extraction of succedaneous tooth or some other tooth or teeth

2. Molar distalization or expansion

Once space is achieved, surgical exposure of the tooth is performed

8. Surgical Exposure

Apically Repositioned Flap

The apically positioned flap is a split-thickness pedicle reflected from the edentulous area (lateral to the area in the case of an impaction) (**Figure 5**).

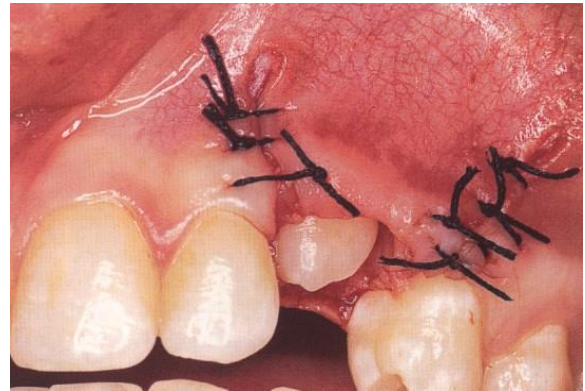

Figure 5: Apically positioned flap.

Disadvantages

The higher tendency for apical gingival position and greater clinical crown length may be unaesthetic in the patient with a high smiling lip line [12]. Apically positioned flap showed apical migration of the gingival margin, bone loss, and attachment loss even though the zone of attached gingiva was wider. Negative esthetic effects, such as increased clinical crown length, increased width of attached tissue, gingival scarring, and intrusive relapse were evident in the teeth treated with an apically positioned flap.

9. Closed Eruption Technique

The closed-eruption technique is believed by some to be the best method of uncovering labially impacted teeth, especially if the tooth is located high above the mucogingival junction or deep in the alveolus where an apically positioned flap may be difficult or impossible to use successfully [13]. The crown of the tooth is exposed, an attachment is fixed to it, and the flap is sutured back over the crown.

Advantages

Some clinicians believe that the closed-eruption method replicates natural tooth eruption and therefore produces the best esthetic and periodontal results.

Disadvantage

High profile brackets may lead to button holing or breakdown of

overlying tissue due to lack of buccal bone and relative tightness of the replaced flap [14]. If the tooth is impacted in the middle of the alveolus or high in the vestibule near the nasal spine, the closed-eruption technique may be the treatment of choice. However, if the tooth requires more attached gingiva or is displaced lateral to the edentulous area, an apically positioned flap may be the best choice. The keratinized tissue be placed to cover CEJ and 2-3mm of crown as the new gingival attachment prevents the marginal bone loss and the gingival recession [15]. The attached gingival is made available by apically repositioned flap, a laterally repositioned pedicle graft, or a free gingival graft.

10. Tunnel Procedure

The extraction of the deciduous tooth provided a natural osseous tunnel, which was easily extended by drilling, to reach the cusp of the impacted tooth (**Figure 6**).

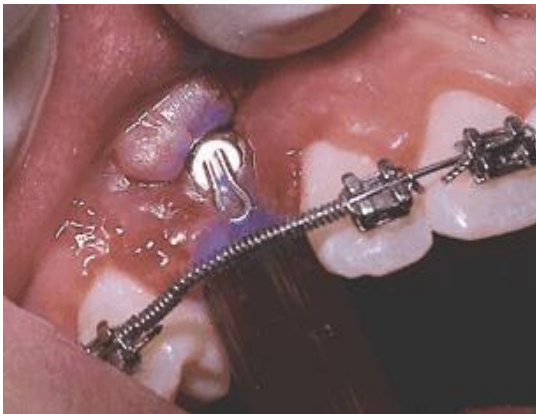

Figure 6: Tunnel Technique.

Traction through the tunnel ensured an eruption path that closely follows the physiologic pattern [15]. The impacted tooth was orthodontically moved between two normally spaced cortical plates toward the center of the alveolar ridge, where some gingiva was present even on the facial aspect. Deep infra-osseous canines associated with persistent deciduous teeth may be successfully and safely treated by repositioned flap and tunnel traction toward the center of the alveolar ridge.

Advantage

Physiologic attachment levels without gingival recession and adequate amounts of gingiva may be obtained and maintained on the treated teeth [16]. No gingival augmentation procedure is required and the natural appearance of the tissues may be preserved. The deep infra-osseous canines were brought into the arch and properly aligned without complaints of significant discomfort, neither during the postoperative period nor during traction. The time needed to move the impacted teeth into the arch, was not unusually long

Mode of Attachment

It should be emphasized that in the surgical exposure of an im-

acted tooth, only enough bone should be removed to allow for the placement of a bracket and that during the procedure the CEJ should not be intentionally exposed. 17 Different methods of attachment to the impacted tooth have been suggested, including lasso wires, threaded pins, orthodontic bands, simple eye-let, crowns, wire ligatures, chain links, auxiliary springs directly bonded brackets and magnets.

Mode of Traction

By using ligature wire, elastic thread, elastomeric chains, coil springs, NiTi arch wire, Ballista spring, Killroy spring, Cantilever spring [18].

11. Anchor Unit

It is necessary to develop a rigid anchor base against which to pit the forces required to reduce impaction. A heavy and a more rigid arch wire is placed into the brackets of all teeth of the fully aligned arch so that there is no distortion of the arch wire [19]. Headgear, intramaxillary elastics, modified removable appliances and soldered palatal or lingual bars also provides a solid anchorage base.

12. Retention Protocol

Fibrotomy and bonded fixed retainers are necessary [20].

13. When to Extract an Impacted Tooth

(1) If it is ankylosed and cannot be transplanted, (2) if it is undergoing external or internal root resorption, (3) if its root is severely dilacerated, (4) if the impaction is severe (and orthodontic movement will jeopardize the adjacent teeth) (5) if the occlusion is acceptable, without the impacted teeth (6) if there are pathologic changes (e.g., cystic formation, infection), and the patient does not desire orthodontic treatment [21].

Dentigerous cysts involved with the impacted teeth

Large dentigerous cysts in the mixed dentition are generally associated with jaw deformity and dislocation of one or more germs of permanent teeth.

Treatment Options: Treatment by enucleation will result in incomplete removal of the epithelium around the neck of the tooth crown or accidental dislodgement of the tooth during the curettage process. Marsupialization involves opening the cyst into the oral cavity at its most superficial point and maintaining the patency of this orifice with the fusion of the cut linings of the cyst and the oral mucosa [22]. Any attempt to apply orthodontic traction to the tooth at this time will extrude ahead of the advancing bone, thereby weakening its bony and periodontal support. Orthodontic treatment is deferred only after enough filling in of the bone takes place.

Incisor Impaction: An impacted maxillary central incisor is more conspicuous to parents. Typically, this occurs when the child is between 8 and 10 years of age (**Figure 7**).

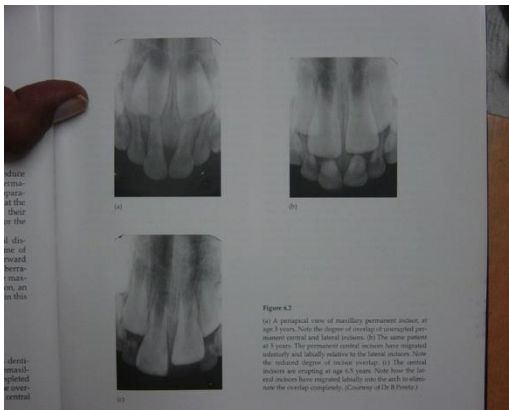


Figure 7: Central Incisor impaction.

Cause

The incisor is prevented from erupting into the arch because of the presence of a heavy band of tissue physically obstructing eruption due to premature loss of the deciduous incisor tooth.

Treatment

Treatment of this type of soft tissue impaction consists of surgically making a “window” in the tissue at the incisal edge of the tooth [23]. This opening is packed with a periodontal dressing for 1 to 2 weeks so that the tissue does not heal back over the incisal edge. The incisor tooth is then allowed to erupt through the opening.

Second Molar Impaction: Incidence 3 in every 1000 mandibular second molars. The usual age at presentation is between 11 and 13 years. More often than not, the mesial marginal ridge of the second molar is “caught” below the distal contact of the first molar [24]. The methods of uprighting these impacted teeth include

1. Surgical repositioning and orthodontic repositioning.
2. Extract the second molars and allowing the third molars to erupt in their place
3. Auto transplantation.

Surgical Uprighting

Involves judicious amount of bone removed and exposure of the occlusal surface of the tooth with deliberate wedging of the tooth between the distal bone and the distal surface of the first molar tooth is performed.

Drawbacks: Loss of vitality, stunted root formation, an-kylosis, and resorption of the second molar

Advantages: Quick and easy procedure with minimal morbidity and good long-term prognosis since the tooth is not removed from the socket, and in many cases the apical vessels probably remain intact [25].

Orthodontic Uprighting

It is usually necessary to effect distalizing as well as eruptive forces. To optimize distalization, it is advantageous to remove the third molar teeth, if present. A variety of methods include separators, super elastic wire ,open coil springs, and segmental springs. In mild impactions, all that may be necessary is to “dislodge” the second molar from its trapped position under the distal bulge of the first molar. This can be accomplished either by a simple elastic separator or by using a twisted brass wire inserted around the contact point.

Transplantation

There has also been very limited success in extracting the second molar and transplanting the third molar into the second molar socket probably because of the lack of bone remaining distal to the second molars. Pulpal calcification and degenerative changes has been noted with transplanted teeth [26].

Premolar Impaction: The tooth is surgically uncovered and an attachment bonded onto it. A traction force is applied and the tooth erupted into the arch. Another treatment option is to extract the impacted tooth and treat the patient as if the impacted premolar was congenitally missing [27].

Mandibular second premolar: Crowding and space loss due to early extraction of the deciduous predecessor. Abnormal premolar orientation due to abnormal angulation of tooth germ. Infra-occluded second deciduous molars.

Treatment Options

1. Space created for the impacted tooth
2. Space holding device used when deciduous tooth is removed. A single rigid bar may be bonded or banded to the first premolar and molar tooth. The impacted tooth is directed with labial and extrusive force.

14. Conclusion

Management of the impacted teeth is one of the greatest challenge for orthodontist. Success of the treatment depends upon patient cooperation, Age of patient, Proper diagnosis, Level of impaction, Inclination and Depth of impaction, Amount of root formation, Type of exposure of tooth, Amount of bone removal, Type of attachment, Orthodontic traction. All these parameter plays important role when managing impacted teeth to achieve

good occlusion in the arch, gingival level, and integrity of periodontium.

References

1. Power SM, Short MB. An investigation into the response of palatally displaced canines to the removal of deciduous canines and an assessment of factors contributing to a favourable eruption. *Br J Orthod.* 1993;20(3):215-23.
2. Litsas G, Ahu Acar. A review of early displaced maxillary canines: Etiology, diagnosis and interceptive treatment. *Open Dent J.* 2011;5:39-47.
3. Bishara SE. Impacted maxillary canines: A review. *Am J Orthod Dentofacial Orthop.* 1992;101(2):159-71.
4. Ericson S, Kurol J. Early treatment of palatally erupting maxillary canines by extraction of the primary canines. *Eur J Orthod.* 1988;10(4):283-95.
5. Mitchell L, editor. *An Introduction to Orthodontics.* 3rd ed. New York: Oxford University Press. 2007;pp:147-56.
6. Jacoby H. The etiology of maxillary canine impactions. *Am J Orthod.* 1983;84(2):125-32.
7. Richardson G, Russell KA. A review of impacted permanent maxillary cuspids -- diagnosis and prevention. *J Can Dent Assoc.* 2000;66(9):497-501.
8. Becker A, editor. *The orthodontic treatment of impacted teeth.* 2nd ed. Abingdon, Oxon, England: Informa Healthcare. 2007; pp:1-228.
9. Peck S, Peck L, Kataja M. The palatally displaced canine as a dental anomaly of genetic origin. *Angle Orthod.* 1994;64(4):249-56.
10. Baccetti T. A controlled study of associated dental anomalies. *Angle Orthod.* 1998;68(3):267-74.
11. Shafer WG, Hine MK, Levy BM, editors. *A textbook of oral pathology.* 2nd ed. Philadelphia: WB Saunders. 1963;pp:2-75.
12. Ericson S, Kurol J. Longitudinal study and analysis of clinical supervision of maxillary canine eruption. *Community Dent Oral Epidemiol.* 1986;14(3):112-6.
13. Ericson S, Kurol J. Radiographic examination of ectopically erupting maxillary canines. *Am J Orthod Dentofacial Orthop.* 1987;91(6):483-92.
14. Bedoya MM, Park JH. A review of the diagnosis and management of impacted maxillary canines. *J Am Dent Assoc.* 2009;140(12):1485-93.
15. Kokich VG. Surgical and orthodontic management of impacted maxillary canines. *Am J Orthod Dentofacial Orthop.* 2004;126(3):278-83.
16. Jacoby H. The "ballista spring" system for impacted teeth. *Am J Orthod.* 1979;75(2):143-51.
17. Crescini A, Giorgetti R, Cortellini P, Clauser C, Pini Prato GP. Tunnel traction of infraosseous impacted maxillary canines. A three-year periodontal follow-up. *Am J Orthod Dentofacial Orthop.* 1994;105(1):61-72.
18. Darendeliler AM. Treatment of an impacted canine with magnets. *J Clin Orthod.* 1994;28:639-43.
19. Larry CFLi, Ricky WK Wong, Nigel M King. Orthodontic traction of impacted canine using magnet: A case report. *Cases J.* 2008;1:382.
20. Lindauer SJ, Isaacson RJ. One-couple orthodontic appliance systems. *Semin Orthod.* 1995;1(1):12-24.
21. Samuels RH, Rudge SJ. Two-archwire technique for alignment of impacted teeth. *J Clin Orthod.* 1997;31(3):183-7.
22. Ross LI. Nickel titanium closed-coil spring for extrusion of impacted canines. *J Clin Orthod.* 1999;33:74-7.
23. Sinha PK, Nanda RS. Management of impacted maxillary canines using mandibular Anchorage. *Am J Orthod Dentofacial Orthop.* 1999;115(3):332-6.
24. Kalra V. The k-9 spring for alignment of impacted canines. *J Clin Orthod.* 2000;34(10):606-10.
25. Hauser C. Eruption of impacted canines with an australian helical archwire. *J Clin Orthod.* 2000;34(9):538-41.
26. Bowman SJ, Carano A. The monkey hook: An auxiliary for impacted, rotated, and displaced teeth. *J Clin Orthod.* 2002;36(7):375-8.
27. Park HS, Kwon OW, Sung JH. Micro-implant anchorage for forced eruption of impacted canines. *J Clin Orthod.* 2004;38(5):297-302.